

# Health Supervision for Children With Achondroplasia

Committee on Genetics

This set of guidelines is designed to assist the pediatrician in caring for children with achondroplasia confirmed by radiographs and physical features. Although pediatricians usually first see children with achondroplasia during infancy, occasionally they are called on to advise the pregnant woman who has been informed of the prenatal diagnosis of achondroplasia or asked to examine the newborn to help establish the diagnosis. Therefore, these guidelines offer advice for these situations as well.

Achondroplasia is the most common form of disproportionate short stature.<sup>1</sup> The diagnosis is based on very specific features on the radiographs, which include a contracted base of the skull, a square shape to the pelvis with a small sacrosciatic notch, short pedicles of the vertebrae, rhizomelic (proximal) shortening of the long bones, trident hands, a normal length trunk, proximal femoral radiolucency, and, by mid-childhood, a characteristic chevron shape of the distal femoral epiphysis. Hypochondroplasia and thanatophoric dysplasia are part of the differential diagnosis, but achondroplasia can be distinguished from these because the changes in hypochondroplasia are milder and the changes in thanatophoric dysplasia are much more severe and invariably lethal. Achondroplasia is an autosomal dominant disorder, but approximately 75% of cases represent new dominant mutations. The gene for achondroplasia has recently been found. Achondroplasia is due to a change in the genetic information for fibroblast growth factor receptor 3.<sup>2,3</sup> Almost all of the mutations have been found to occur in exactly the same spot. Now that the gene has been found and the mutation known, potential therapies and diagnostic methodologies are likely to be developed. A great deal is known about the natural history of the disorder that can be shared with the family. The average adult height in achondroplasia is about 4 ft for both men and women (Figs 1 through 6).<sup>4</sup> Other features include disproportionate short stature, with shortening of the proximal segment of the limbs, a promi-

nent forehead, a flattened midface, and an average-sized trunk. The head usually appears relatively large compared with the body. The most common complication, occurring in adulthood, is related to lumbosacral spinal stenosis with compression of the spinal cord or nerve roots.<sup>5,6</sup> This complication is usually treatable by surgical decompression, if diagnosed at an early stage.

Children affected with achondroplasia frequently have delayed motor milestones, otitis media, and bowing of the knees (Fig 7).<sup>7</sup> Occasionally in infancy or early childhood there is symptomatic airway obstruction, development of thoracolumbar kyphosis, symptomatic hydrocephalus, or symptomatic upper cord compression. Most individuals with achondroplasia are of normal intelligence and are able to lead independent and productive lives.<sup>8</sup> Because of their disproportionate short stature, however, a number of psychosocial problems can arise. Families can benefit from anticipatory guidance and the opportunity to learn from other families with children of disproportionate short stature.

The following guidelines are designed to help the pediatrician care for children with achondroplasia and their families. Issues that need to be addressed at various age groups are discussed (Table). These guidelines are not appropriate for other chondrodysplasias, because each type has its own natural history, complications, and specific guidelines. It is important that parents also consult a physician with experience and expertise concerning achondroplasia early in their child's development, because these guidelines are intended for the general pediatrician without such experience.

## THE PRENATAL VISIT

Pediatricians may be called upon to counsel a family in which a fetus has achondroplasia or is suspected to have achondroplasia. In some settings, the pediatrician will be the primary resource for counseling a family. At other times, counseling may already have been provided to the family by a clinical geneticist and/or the obstetrician. Because of a previous relationship with the family, however, the pediatrician may be called on to review this information and to assist the family in the decision-making process.

The diagnosis of achondroplasia in the fetus is most often only made with certainty when one or both parents have this condition. In this circumstance the parents are usually knowledgeable about

The recommendations in this policy statement do not indicate an exclusive course of treatment for children with genetic disorders, but are meant to supplement anticipatory guidelines available for treating the normal child provided in the AAP publication, *Guidelines for Health Supervision*. They are intended to assist the pediatrician in helping children with genetic conditions to participate fully in life. Diagnosis and treatment of genetic disorders are changing rapidly. Therefore, pediatricians are encouraged to view these guidelines in light of evolving scientific information. Clinical geneticists may be a valuable resource for the pediatrician seeking additional information or consultation.

PEDIATRICS (ISSN 0031 4005). Copyright © 1995 by the American Academy of Pediatrics.

**TABLE. Achondroplasia Guidelines for Health Supervision\***

Age	Infancy, 1 mo–1 y					Early Childhood, 1–5 y				Late Childhood (5–13 y), Annual	Adolescence (13–21 y), Annual	
	Prenatal	Neonatal	2 mo	4 mo	6 mo	9 mo	12 mo	15 mo	18 mo			24 mo
<b>Diagnosis</b>												
X-ray film	Whenever the diagnosis is suspected.											
Review phenotype	Whenever the diagnosis is suspected.											
Review proportions	Whenever the diagnosis is suspected.											
<b>Genetic Counseling</b>												
Early intervention	●											
Recurrence risks	●					●						●
Reproductive options						●					●	●
Family support	●					●			●		●	●
Support groups	●					●			●		●	●
Long-term planning						●			●		●	●
<b>Medical Evaluation</b>												
Growth/weight/OFC	●	●	●	●	●	●	●	●	●		●	●
Orthopedic—if complication												
Neurologic—if complication												
Hearing						●R			●R	●R	●R	
Social readiness						S			S	S	S	
Orthodontics										R	R	R
<b>Medical Evaluation</b>												
X-ray films—only to make diagnosis or if complication												
Ultrasound—of brain ventricle size	●											
<b>Social Adjustment</b>												
Psychosocial				S		S			S		S	S
Behavior and development	S/O	S/O	S/O	S/O		S/O	S/O	S/O	S/O		S/O	S/O
School										O	O	O
Sexuality												●

\* Assure compliance with the American Academy of Pediatrics "Recommendations for Preventive Pediatric Health Care."  
 ● = to be performed; S = subjective, by history; O = objective, by a standard testing method; and R = discuss referral to a specialist.

the disorder, the inheritance, and the prognosis for the offspring.

In most situations in which the parents have normal stature, the diagnosis may only be suspected based on the observation of disproportionately short limbs in the fetus by ultrasound. With the frequent use of ultrasound, approximately one third of cases of fetal achondroplasia are suspected prenatally. However, disproportionately short limbs are observed in a heterogeneous group of conditions. In the majority of these cases, the specific diagnosis cannot be made with certainty except by radiography late in pregnancy or more usually after birth. In these cases, caution should be exercised when counseling the family. In those infrequent cases in which the diagnosis is unequivocally established either because of the familial nature of the disorder or by prenatal radiography, the pediatrician may discuss the following issues as appropriate.

1. Review, confirm, and demonstrate laboratory or imaging studies leading to the diagnosis.
2. Explain the mechanisms for occurrence or recurrence of achondroplasia in the fetus and the recurrence risk for the family.
3. At least 75% of cases of achondroplasia occur in families in which both parents have average stature and achondroplasia in the offspring occurs due to sporadic mutation in the gene.
4. Review the natural history and manifestations of achondroplasia, including variability.<sup>1</sup>
5. Discuss further studies that should be done, particularly those to confirm the diagnosis in the newborn period. If miscarriage, stillbirth, or termination occurs, confirmation of diagnosis is important for counseling family members about recurrence.
6. Review the currently available treatments and interventions. This discussion needs to include the

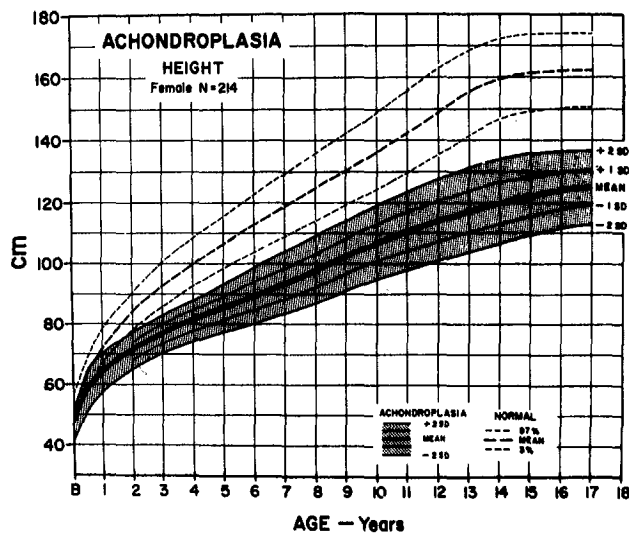


Fig 1. Height for females with achondroplasia (mean  $\pm$  SD) compared to normal standard curves. Graph is derived from 214 females. (From Horton et al.<sup>4</sup>)

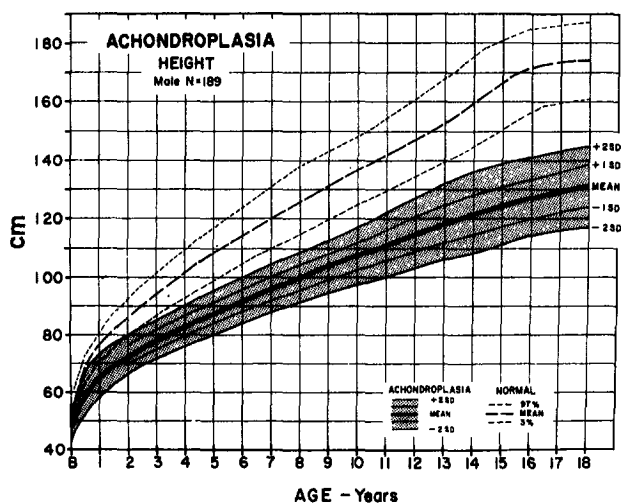


Fig 2. Height for males with achondroplasia (mean  $\pm$  2SD) compared to normal standard curves. Graph is derived from 189 males. (From Horton et al.<sup>4</sup>)

- efficacy, complications, side effects, costs, and other burdens of these treatments. Discuss possible future treatments and interventions.
- Explore the options available to the family for the management and rearing of the child using a non-directive approach. In cases of early prenatal diagnosis, these may include discussion of pregnancy termination, as well as continuation of pregnancy and rearing of the affected child at home, foster care, or adoption. When both parents are of disproportionate short stature, the possibility of double heterozygosity or homozygosity for achondroplasia must be assessed. Infants with homozygous achondroplasia usually are either stillborn or die shortly after birth. Homozygous achondroplasia can usually be diagnosed prenatally.
  - If the mother is affected with achondroplasia, a cesarean section must be performed because of a

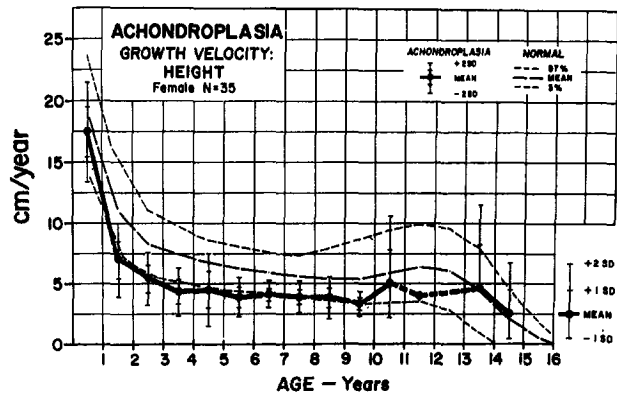
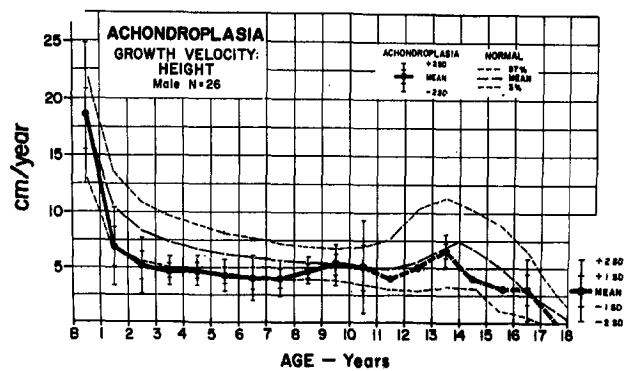


Fig 3. Mean growth velocities (solid line) for males (top) and females (bottom) with achondroplasia compared to normal growth velocity curves (dashed lines, 3rd percentile, mean, 97th percentile). Data are derived from 26 males and 35 females. (From Horton et al.<sup>4</sup>)

small pelvis.<sup>9</sup> This surgical procedure usually involves general anesthesia because of the mother's spinal stenosis and the consequent risk associated with conduction (spinal/epidural) anesthesia. A mother affected with achondroplasia may develop respiratory compromise in the third trimester of pregnancy, so baseline pulmonary function studies should be done. A pregnancy at risk for homozygosity should be followed with ultrasound measurements at 14, 16, 18, 22, and 32 weeks of gestation in order to distinguish homozygosity or heterozygosity from normal growth patterns in the fetus. New DNA diagnostic studies are likely to become available.

#### HEALTH SUPERVISION FROM BIRTH TO 1 MONTH—NEWBORNS

##### Examination

- Confirm the diagnosis by radiographic studies (the diagnosis of approximately 20% of patients with achondroplasia has been missed in the past, because it was not suspected on physical examination in the newborn period and consequently no radiographs were obtained).
- Document measurements, including arm span, occipital frontal circumference (OFC), body length, and upper to lower body segment ratio; note these measurements on the achondroplasia special growth charts at the end of this document. Review

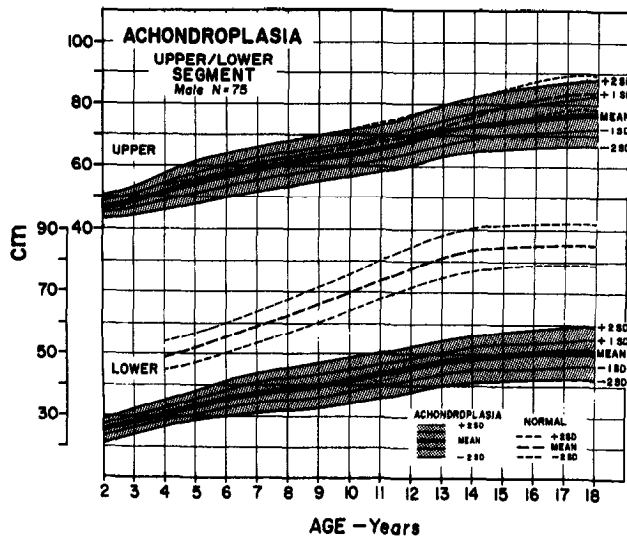


Fig 4. Upper and lower segment lengths for males (top) and (bottom) with achondroplasia (mean  $\neq$  SD). Data are derived from 75 males and 95 females. (From Horton et al.<sup>4</sup>)

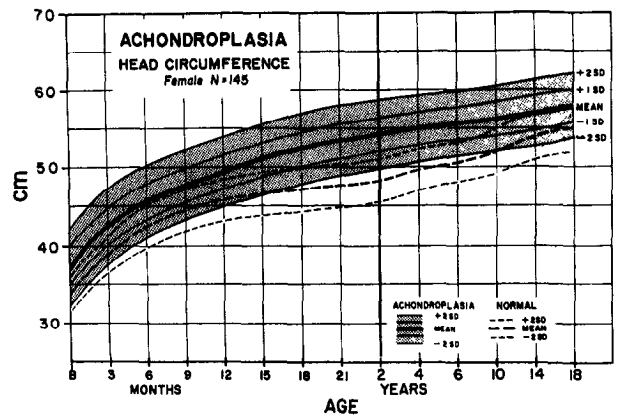


Fig 5. Head circumference for females with achondroplasia compared to normal curves (dashed lines). Data are derived from 145 females. (From Horton et al.<sup>4</sup>)

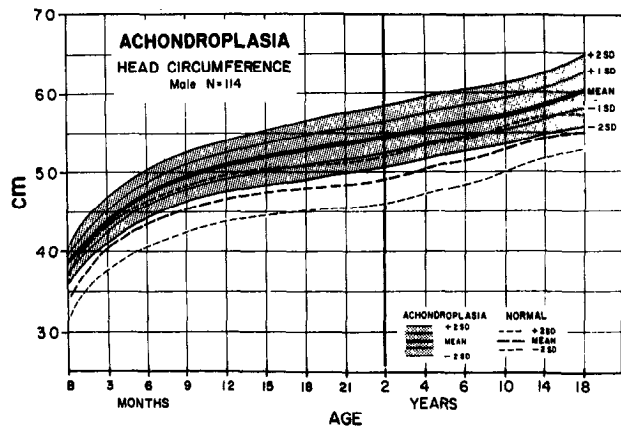
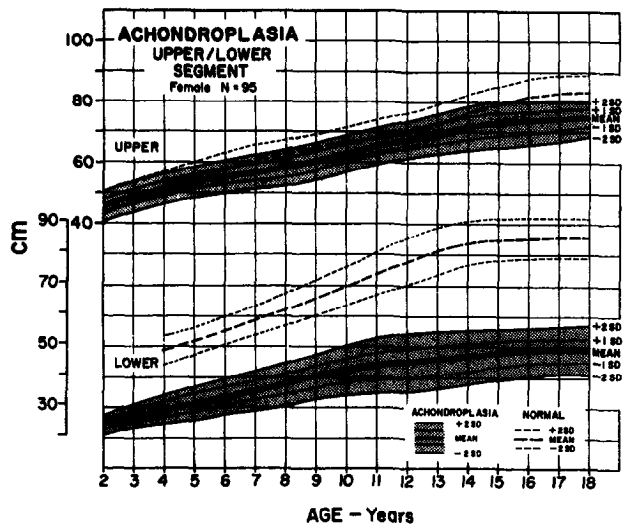


Fig 6. Head circumference for males with achondroplasia compared to normal curves (dashed lines). Data are derived from 114 females. (From Horton et al.<sup>4</sup>)

the phenotype with the parents and discuss the specific findings with both parents whenever possible.

- The OFC should be measured monthly during the first year. Ultrasound studies of the brain to determine ventricular size should be considered if the fontanelle size is unusually large, OFC increases disproportionately, or symptoms of hydrocephalus develop.

#### Anticipatory Guidance

- Discuss the specific findings of achondroplasia with the parents, including:
  - Autosomal dominant inheritance. About 75% of cases are new mutations. Germline mosaicism (in which some germ cells are derived from a normal cell line and some are from a cell line with a mutation) has been reported, but clearly the risk of recurrence in sporadic cases is far below 1%.
  - Most individuals with achondroplasia have normal intelligence and normal life expectancy.

- Growth hormone and other drug therapies are not effective in increasing stature. Experimental work is being done on leg-lengthening procedures at an older age.<sup>10,11</sup>

- Special achondroplasia growth curves and infant development charts have been developed, and the final expected adult height for persons with achondroplasia is in the range of about 4 ft.<sup>4</sup>

- Discuss the following possible severe medical complications:

- Unexpected infant death in less than 3% of those affected, usually only in the most severe cases.<sup>12</sup> Severe upper airway obstruction in less than 5% of those affected, but consider sleep studies if there appears to be a problem with breathing at rest or during sleep, especially if developmental landmarks lag.<sup>13</sup>
- Restrictive pulmonary disease with or without reactive airway disease occurs in less than 5% of children with achondroplasia who are younger than 3 years<sup>13</sup>; consider pulse oximetry or evaluation for cor pulmonale if there are signs of breathing problems.
- Development of thoracolumbar kyphosis is associated with unsupported sitting before there

## DEVELOPMENTAL SCREENING TESTS IN ACHONDROPLASIA

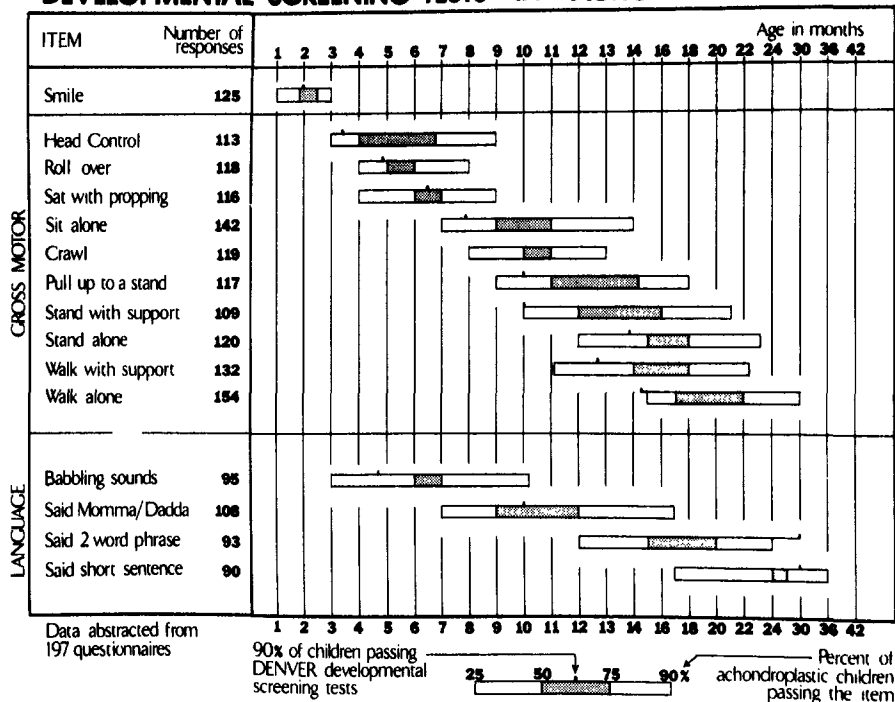


Fig 7. Developmental screening tests in achondroplasia. The 25th, 50th, 75th, and 90th centiles are determined by linear interpolation. (From Todorov et al.<sup>7</sup>).

is adequate trunk muscle strength.<sup>14</sup>

- All infants with achondroplasia have a relatively small foramen magnum, but few become symptomatic from cord compression at the cervicomedullary junction.<sup>15</sup> This complication may be manifested by signs and symptoms of a high cervical myelopathy, central apnea, or both.<sup>16</sup> Rarely, foramen magnum decompression may be recommended.
  - Hydrocephalus may develop during the first 2 years,<sup>17</sup> so OFC size should be monitored carefully during this time. If a problem is suspected, refer the infant to a pediatric neurologist or pediatric neurosurgeon.
  - The common complication of spinal stenosis rarely occurs in childhood but manifests in older individuals with numbness, weakness, and altered deep tendon reflexes.<sup>18</sup> Children with severe thoracolumbar kyphosis are at greater risk for this problem. It is for this reason that unsupported sitting before there is adequate trunk muscle strength is discouraged.
3. Discuss the psychosocial issues related to disproportionate short stature. Refer the affected individual, or the parent of an affected individual, to a support group such as Little People of America or Human Growth Foundation (see "Resources for New Parents"). If parents do not wish to join a group, they may want to meet with or talk to other affected individuals or parents. Remind parents that most individuals with achondroplasia lead productive, independent lives.
  4. Discuss with the parents how to tell their family and friends about their child's growth problem.
  5. Supply the parents with educational books and pamphlets (see "Resources for New Parents").

6. Discuss the realistic functional problems for affected individuals.
7. Discuss individual resources for support, such as family, clergy, social workers, and friends.
8. Review the prenatal diagnosis and recurrence risks for subsequent pregnancies.

### HEALTH SUPERVISION FROM 1 MONTH TO 1 YEAR—INFANCY

#### Examination

1. Assess growth and development in comparison only to children with achondroplasia.
2. Perform physical examination and appropriate laboratory studies.
3. Review head growth.
4. Consider performing a central nervous system ultrasound at 2, 4, or 6 months if the infant's head size increases rapidly in order to evaluate ventricular size. If the size of the OFC or ventricles is increasing rapidly, refer the infant to a pediatric neurologist or pediatric neurosurgeon. At 6 to 12 months, consider performing additional neuroimaging studies, if appropriate.
5. Check motor development and discuss development; note on the milestone charts for achondroplasia. Expect motor delay but not social or cognitive delay.<sup>7</sup>
6. Watch for low thoracic or high lumbar gibbus (posterior angulation or kyphosis) associated with truncal weakness. It is recommended that parents avoid carrying a child with achondroplasia in curled-up positions. Certain types of child carriers, swingomatics, jolly jumpers, and "um-

rella" strollers tend to increase risk for gibbus. Unsupported sitting should be avoided.<sup>12</sup> Parents should be instructed to provide back support during the first year of life.

7. External rotation of the hips is frequently present and usually spontaneously disappears when the child begins to bear weight. This finding does not require bracing.<sup>19</sup>
8. Check for serous otitis media. Review risk at 6 to 12 months.
9. Arrange sleep studies if any sign of respiratory compromise or delay in developmental milestones is present.
10. Refer the infant to a pediatric neurologist or pediatric neurosurgeon for reflex asymmetry, extreme hypotonia, early hand preference, or excessive head growth.<sup>5,17</sup>
11. Consider magnetic resonance imaging or computed tomography of the foramen magnum region for a severely hypotonic infant or one who has signs of cord compression. Magnetic resonance imaging should include the base of the skull as well as the ventricles and spinal cord (Fig 8).<sup>20,21</sup>
12. Discuss filing for Supplemental Security Income benefits as appropriate.

#### Anticipatory Guidance

1. Review the personal support available to the family.
2. Review contact with support groups.
3. Observe the emotional status of parents and intrafamily relationships.
4. Discuss early intervention services and the importance of normal socializing experiences with other children.
5. Ask the parents if they have educated their family members about achondroplasia; discuss sibling adjustment.
6. Review the increased risk of serous otitis media because of short eustachian tubes. Indicate that an ear examination is needed with any upper respiratory tract infection.
7. Avoid infant carriers that curl up the infant. This does not apply to car safety seats, which should always be used during automobile travel.

#### HEALTH SUPERVISION FROM 1 TO 5 YEARS—EARLY CHILDHOOD

##### Examination

1. Assess the child's growth and development as charted on the achondroplasia growth charts. Obtain lower segment measurements once weight bearing is established.
2. Continue to follow head growth.
3. Continue to watch for thoracolumbar gibbus and development of lumbar lordosis. Discuss avoiding the use of walkers, jumpers, or backpack carriers. Any kyphosis present should disappear as the child begins to bear weight. Weight-bearing and walking may occur late; however, they are expected by 2 years of age. When weight-bearing

begins, the external rotation of the hips should self-correct to a normal orientation within 6 months.

4. Anticipate some bowing of the legs because of fibular overgrowth at the knees and ankles. If bowing leads to an inability to walk, consult a pediatric orthopedist.
5. Check the child's hips for hip flexion contractures. Prescribe exercises that may decrease lumbar lordosis and hip flexion contractures.<sup>19</sup> Check the hips for external rotation. Refer the child to a pediatric orthopedist, if necessary.
6. Speech evaluation should be done no later than 2 years of age. If speech is abnormally delayed conductive hearing loss due to chronic serous otitis media should be excluded.
7. Watch for obstructive sleep apnea. Children with achondroplasia often sweat and snore in association with sleep. If upper airway obstruction is suspected (increased retraction, choking, intermittent breathing, apnea, deep compensatory sighs), further pulmonary evaluation and neurologic examination including somatic sensory-evoked responses, sleep studies, and magnetic resonance imaging are needed.

#### Anticipatory Guidance

1. Consider adapting the home so the child can become independent (lower the light switches, faucets, and supply step stools).
2. Occupational therapy consultation may be needed.
3. Discuss adapting age-appropriate clothing with snapless, easy-opening fasteners and tuckable loops.
4. Discuss adaptation of toys, especially tricycles, to accommodate short limbs.
5. Discuss adaptation of toilets to allow comfortable independent use, with an extended wand for wiping.
6. Discuss the use of a stool during sitting so that the child's feet are not hanging. Feet need support while the child is sitting at a desk or in a chair. A cushion behind the child's back may be required for good posture.
7. Review weight control and eating habits to avoid obesity, which becomes a common problem in mid to late childhood.<sup>22</sup>
8. Discuss orthodontic bracing in the future and the possible need for braces after 5 years of age.
9. Encourage the family to develop activities in which the affected child can take part; avoid gymnastics, high diving, acrobatics, and collision sports.
10. Discuss how to talk with the child and other friends or family members about short stature.
11. Encourage preschool attendance so that the child can learn to socialize in an age-appropriate way, and work with parents to prepare the teacher and the other children so the child is not given unnecessary special privileges.
12. Discuss toileting at school and special preparations needed by the school because of the child's short stature.

## Foramen Magnum Size in Achondroplasia

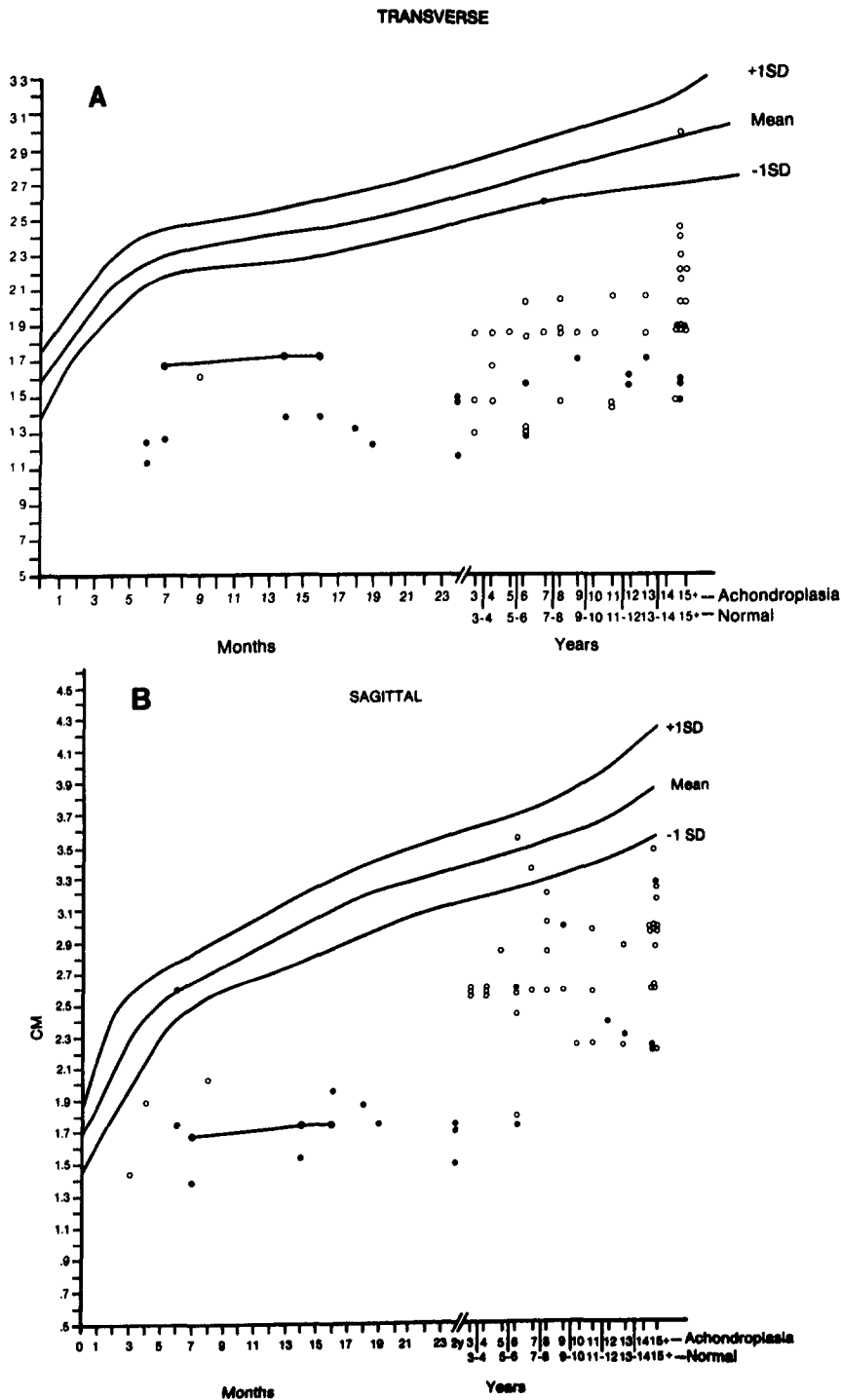


Fig 8. CT measurements of the foramen magnum. A, transverse; B, sagittal. Normals are plotted as mean  $\pm$  1SD. Achondroplasia as individual measurements: the solid circles represent patients with and the open circles patients without evidence of neurologic function.

13. Discourage the child from jumping to decrease unnecessary stress on joints, particularly the joints of the spine.

### HEALTH SUPERVISION FROM 5 TO 13 YEARS—LATE CHILDHOOD

#### Examination

Assess and review the child's growth and development and social adaptation.

#### Anticipatory Guidance

1. Determine school readiness.
2. Discuss preparation of the school and teacher for a child with short stature.
3. Prepare the child for psychosocial situations and discussing issues. Be sure the child can explain why he or she is short and can ask for help in an appropriate way. Children with achondroplasia

- usually are included in the regular education program.
4. Suggest adaptive aids for the school to cope with heavy doors, high doorknobs, reaching for the blackboard, foot support, and a regular-sized desk. Also be sure that the child can use the restroom independently.
  5. Test hearing regularly each year, checking for possible recurrent serous otitis media.
  6. Check deep tendon reflexes yearly for asymmetry or increased reflexes suggesting spinal stenosis.
  7. Continue to assess history for possible obstructive sleep apnea.
  8. Review socialization and foster independence.
  9. Review weight control. The child may need to restrict food intake and eat as little as half as much as an average-sized child eats.
  10. Discuss contact with support groups. It is especially valuable at this age.
  11. Obtain an orthopedic evaluation when the child is approximately 5 years of age in order to make appropriate treatment plans, if necessary.
  12. Emphasize correct posture and encourage the child to consciously decrease lumbar lordosis by "tucking the buttocks under."
  13. Develop an activity program with acceptable activities such as swimming and biking. The child should avoid gymnastics and contact sports because of the potential for neck or back damage due to existing spinal stenosis.
  14. Review orthodontic and speech status.

#### HEALTH SUPERVISION FROM 13 TO 21 YEARS OR OLDER— ADOLESCENCE TO EARLY ADULTHOOD

##### Examination

1. Continue to record parameters.
2. Discuss any signs or symptoms of nerve compression and check deep tendon reflexes, tone, and sensory findings, if indicated.
3. Review weight and diet.

##### Anticipatory Guidance

1. Check on social adaptation.
2. Discuss the diagnosis with the adolescent to be sure that the adolescent has the vocabulary and the understanding of the genetic nature of achondroplasia.
3. Discuss sexuality and reproduction, as well as the necessity for a cesarean section in women for childbirth.<sup>7</sup>
4. Continue orthodontic evaluation.
5. Continue weight counseling.<sup>22</sup>
6. Encourage the family and affected person to set career and life goals high and appropriate, as for other members of the family. Assist in adapting to an independent life and in obtaining a driver's license. (Vocational rehabilitation may pay.)
7. Discuss college, vocational planning and training, and other plans following high school.
8. Foster independence.

9. Continue to encourage participation in social activities and support groups. It is particularly useful during this age period.
10. Assist in transition to adult care, with emphasis on continued monitoring of the spine.

COMMITTEE ON GENETICS, 1994 TO 1995  
Margretta R. Seashore, MD, Chairperson  
Sechin Cho, MD  
Franklin Desposito, MD  
Jack Sherman, MD  
Rebecca S. Wappner, MD  
Miriam G. Wilson, MD

LIAISON REPRESENTATIVES  
Felix de la Cruz, MD,  
National Institutes of Health  
James W. Hanson, MD,  
American College of Medical Genetics  
Jane Lin-Fu, MD, Health Resources  
and Services Administration, DHHS  
Paul McDonough, MD, American College of  
Obstetricians & Gynecologists  
Godfrey Oakley, MD, Centers for  
Disease Control & Prevention

AAP SECTION LIAISON  
Beth A. Pletcher, MD,  
Section on Genetics & Birth Defects

CONSULTANT  
Judith G. Hall, MD

#### RESOURCES FOR NEW PARENTS

Human Growth Foundation  
7777 Leesburg Pike  
Falls Church, VA 22043  
703/883-1773 or 800/451-6434

Little People of America  
PO Box 9897  
Washington, DC 20016  
214/388-9576 or 800/24-DWARF

#### REFERENCES

1. Human achondroplasia. A multidisciplinary approach. Proceedings of the first international symposium. November 19-21, 1986, Rome, Italy. *Basic Life Sci.* 1988;48:1-491
2. Rousseau F, Bonaventure J, Legeai-Mallet L, et al. Mutations in the gene encoding fibroblast growth factor receptor-3 in achondroplasia. *Nature.* 1994;371:252-254
3. Shiang R, Thompson LM, Zhu YZ, et al. Mutations in the transmembrane domain of FGFR3 cause the most common genetic form of dwarfism, achondroplasia. *Cell.* 1994;78:335-342
4. Horton WA, Rotter JL, Rimoin DL, Scott CI, Hall JG. Standard growth curves for achondroplasia. *J Pediatr.* 1978;93:435-438
5. Hecht JT, Butler JJ. Neurologic morbidity associated with achondroplasia. *J Child Neurol.* 1990;5:84-97
6. Pyeritz RE, Sack GH, Udvarhelyi GB. Thoracolumbosacral laminectomy in achondroplasia: long-term results in 22 patients. *Am J Med Genet.* 1987;28:433-444
7. Todorov AB, Scott CI, Warren AE, Leeper JD. Developmental screening tests in achondroplastic children. *Am J Med Genet.* 1981;9:19-23
8. Rogers JG, Perry MA, Rosenberg LA. IQ measurement in children with skeletal dysplasia. *Pediatrics.* 1979;63:894-897
9. Allanson JE, Hall JG. Obstetrics and gynecologic problems in women with chondrodystrophies. *Obstet Gynecol.* 1986;67:74-78
10. Paley D. Current techniques of limb lengthening. *J Pediatr Orthop.* 1988;8:73-92
11. Rimoin DL. Limb lengthening: past, present, and future. *Growth Genet and Hormones.* 1991;7:4-6
12. Pauli RM, Scott CI, Wassman ER, et al. Apnea and sudden unexpected death in infants with achondroplasia. *J Pediatr.* 1984;104:342-348



13. Stokes DC, Phillips JA, Leonard CO, et al. Respiratory complications of achondroplasia. *J Pediatr.* 1983;102:534-541
14. Hall JG. Kyphosis in achondroplasia: probably preventable. *J Pediatr.* 1988;112:166-167
15. Reid CS, Pyeritz RE, Kopits SE, et al. Cervicomedullary compression in young patients with achondroplasia: value of comprehensive neurologic and respiratory evaluation. *J Pediatr.* 1987;110:522-530
16. Nelson FW, Goldie WD, Hecht JT, Butler IJ, Scott CI. Short-latency somatosensory evoked potentials in the management of patients with achondroplasia. *Neurology.* 1984;34:1053-1058
17. Steinbok P, Hall JG, Flodmark O. Hydrocephalus in achondroplasia: the possible role of intracranial venous hypertension. *J Neurosurg.* 1989;71:42-48
18. Hecht JT, Butler IJ, Scott CI. Long-term neurological sequelae in achondroplasia. *Eur J Pediatr.* 1984;143:58-60
19. Siebens AA, Hungerford DS, Kirby NA. Achondroplasia: effectiveness of an orthosis in reducing deformity of the spine. *Arch Phys Med Rehabil.* 1987;68:384-388
20. Hecht JT, Nelson FW, Butler IJ, et al. Computerized tomography of the foramen magnum: achondroplastic values compared to normal standards. *Am J Med Genet.* 1985;20:355-360
21. Hecht JT, Horton WA, Reid CS, Pyeritz RE, Chakraborty R. Growth of the foramen magnum in achondroplasia. *Am J Med Genet.* 1989;32:528-535
22. Hecht JT, Hood OJ, Schwartz RJ, et al. Obesity in achondroplasia. *Am J Med Genet.* 1988;31:597-602